

In the Name of Allah, the most beneficent and the most merciful
Assalamu Alaikkum Varahmathullah

Date: 19-10-2012

Dear Brothers and Sisters,

We request your Kind Attention for Humanitarian Support

One of our brothers Mr. Thameem Deen (39 years old, S/o Mr. Sheik Dawood (Ex-Police man), Puduavalasai, Ramanathapuram Dist, Tamilnadu, India) is facing Risky situation in his life due to his Heart Attack (second attack).

He is being hospitalized presently at [Madurai Vadamalayan Multi-Specialty Hospital](#) and the doctors advised for early Bypass surgery to save his life. I herewith attached his medical reports which emphasize his surgery.

Being under Poverty line and having such serious health issue became a tragedy to his life in which he has a wife and two children.

He has struggled his maximum level to manage his earlier Medical expenses which were around INR 200,000 (US\$4000) but for the further Treatment, which is very critical as well as Expensive (around INR 400,000 (US\$8000)), he is in need of our financial support.

We, as friends and relatives may contribute our best **to Save his Life**

We shall pay our Zakat/Sadhaka to our dearest one at this situation, through which we may be benefited along with him, Insha Allaah.

We expecting your support before 15th November 2012.

فَكَانَ مَا الْأَرْضِ فِي فَسَادٍ أَوْ نَفْسٍ بَغِيرِ نَفْسًا قَتَلَ مَنْ أَنَّهُ إِسْرَائِيلَ بَنِي عَلَى كَتَبْنَا ذَلِكَ أَجَلٍ مِنْ
إِنَّ نُمَّ بِالْبَيِّنَاتِ رُسُلُنَا جَاءَتْهُمْ وَلَقَدْ ۖ جَمِيعًا النَّاسَ أَحْيَا فَكَانَ مَا أَحْيَاهَا وَمَنْ جَمِيعًا النَّاسَ قَتَلَ
لَمْ يُسْرِفُونَ الْأَرْضِ فِي ذَلِكَ بَعْدَ مِنْهُمْ كَثِيرًا

Sahih International

Because of that, We decreed upon the Children of Israel that whoever kills a soul unless for a soul or for corruption [done] in the land - it is as if he had slain mankind entirely. And whoever saves one - it is as if he had saved mankind entirely.....(Al Qur'an 5:32)

Regards,
Abdul Haleem ,
050-8845461

Send your donations directly to the victims mistress account

SASMIYA BEGAM

ICICI BANK, PANAIKULAM BR

A/C NO: 617001500436



VADAMALAYAN HOSPITALS™

DISCHARGE SUMMARY



CNS – NFND

INVESTIGATION DONE:

17.10.2012 CAG Report:

Triple Vessel Disease

Plan: Coronary Artery By-pass Graft Surgery

16-10-2012:

BLOOD GLUCOSE SUGAR :105, Creatinine : 1.0 mg/dl, Potassium : 4.6 mEq/L, Urea : 28 mg/dl, Bleeding Time :3 MIN, Blood Group : A POSITIVE , Clotting Time :6 MIN, Haemoglobin : 11.0 gm/dl, HBsAg (Screening test) :NEGATIVE, HCV Ab (Screening test) :NON REACTIVE , Blood Glucose (Fasting) : 129 mg/dl, Total Cholesterol : 108 mg/dl, Tryglycerides : 157 mg/dl, HDL Cholesterol : 38 mg/dl, LDL Cholesterol : 39 mg/dl. VLDL Cholesterol : 31 mg/dl

17-10-2012:

Blood Glucose (Fasting) : 123 mg/dl

TREATMENT GIVEN:

Tab. Cardace 2.5mg od, Tab. Cardivas 6.25mg bd, Tab. Dytor 10mg od, Tab. Epilenice 25mg od, Tab. Tonact 80mg hs, Tab. Prax 10mg hs, Tab. Pan D 40mg od, Tab. Ecosprin 150mg hs, Tab. Alprax 0.5mg hs

DISCHARGE MEDICATION:

1. Tab. Cardace	2.5mg	1-0-0
2. Tab. Cardivas	6.25mg	1-0-1
3. Tab. Tonact	80mg	0-0-1
4. Tab. Prax	10mg	0-0-1
5. Tab. Pan D	40mg	1-0-0
6. Tab. Ecosprin	150mg	0-0-1
7. Tab. Alprax	0.5mg	0-0-1
8. Tab. Dytor LS plus	10+25mg	1-0-0 (Alternate days)

For Emergency Contact No: 8870001033

ICD CODE:

PRIMARY ICD CODE :

I25.1 Atherosclerotic heart disease

PRIMARY ICD CODE :

I21.0 Acute transmural myocardial infarction of anterior wall

Dr
✓

Dr. M. Srinivasan, M.D., D.M.,
(Cardiologist)

Dr. M. SRINIVASAN M.D., D.M.,
Sr. Consultant Cardiologist
Vadamalayan Hospital :
9-A, Vallabhai Road, Chokkikulam,
Madurai - 625 002.

Hospital : ☎
2532595 / 2532180 / 2632335
2536296 / 4361022 / 4361033
For Emergency : 650 1033

Date :

17/10/12


To:

DR. JOSEPH RAJAN,,

Dear sir,

Thank you for referring Sir, Mr. S. Thameemudeen, He had Triple Vessel Disease
and need early CABG

Thanking you,



DR.M.SRINIVASAN.MD.,DM (Cardiologist)



VADAMALAYAN HEART FOUNDATION

Unit of Vadamarayan Hospitals,
9-A, Vallabai Road, Chokkikulam, Madurai - 2.



CARDIAC CATHETERISATION AND ANGIOGRAPHY REPORT

Name : Mr. Thameemdeen Age : 39yrs/M IP No: 2012A3114
Cath : Date : 17.10.2012

DONE BY : DR. M. SRINIVASAN.MD, DM, (CARDIO)

REFERRED BY : DR. JOSEPH RAJAN.,

DIAGNOSIS : RECENT ANTERIOR WALL MYOCARDIAL INFARCTION

ROUTE : Right Radial

LM : Long bifurcates Normal

LAD : Type III, 100% occulted at ostium receives collaterals from RCA and LCX . LAD is about 1.5mm LAD and D1 are graftable

LCX : Non dominant, OM1 1.5mm has ostial 70% lesion. Mid LCX has subtotal occlusion. OM2, OM3 are graftable

RCA : Dominant, mid segment RCA has 40% long lesion. RCA gives graft III collaterals to LAD

LIMA : Normal

IMPRESSION : Triple Vessel Disease

PLAN : Coronary Artery By-pass Graft surgery


DR. M. SRINIVASAN.MD, DM, (CARDIO).



VADAMALAYAN HEART FOUNDATION

At Vadamalayan Hospitals, Madurai

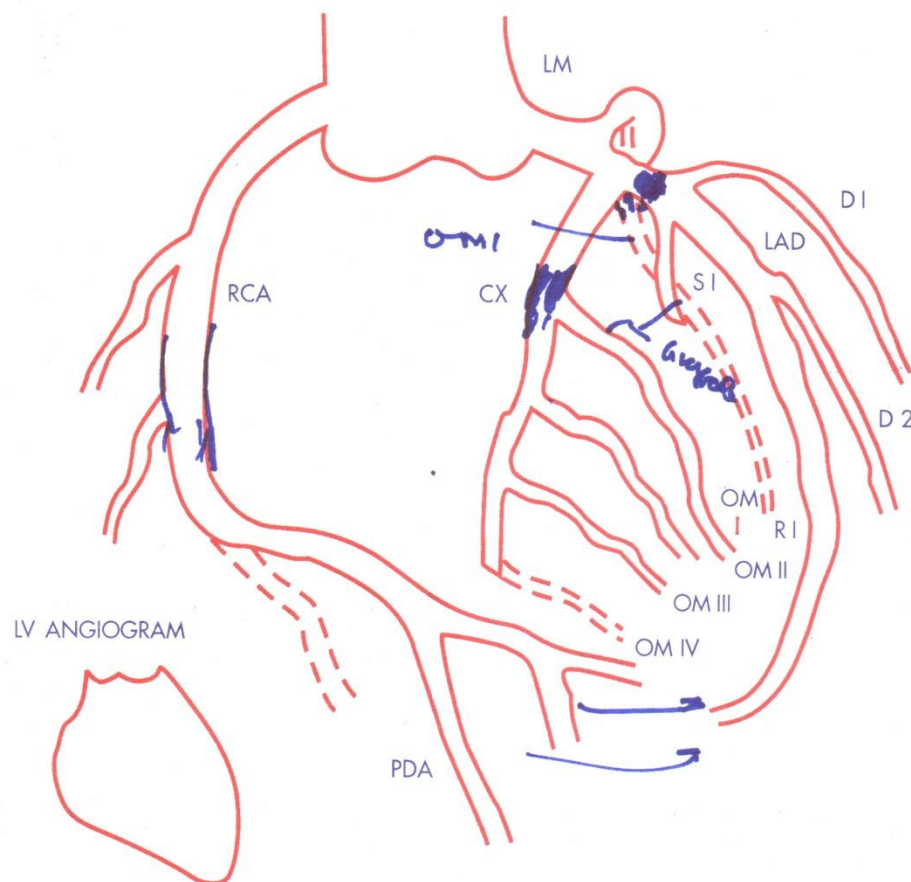
(ISO 9001 : 2000 Certified)

9-A, Vallabai Road, Chokkikulam, Madurai - 2.

CARDIOLOGY

CORONARY ANGIOGRAM REPORT

Name Mr. Thameedheen Age 33 Sex Male
Cath No. Date 17.10.12 Done by



N - NORMAL
A - HYPOKINESIA
B - AKINESIA
C - DYSKINESIA
D - ANEURYSM



Vadamalayan Hospitals

Unit I : 9A, Vallabai Road, Chokkikulam, Madurai - 625 002. ☎ : 2545400 (100 Lines)
Unit II : 77-80, Chinnakadai Street, Madurai - 625 001. ☎ 437 1000, 437 1011
Unit III : 15, Jawahar Road, Chokkikulam, Madurai - 625 002. ☎
Phone : 2545400 (100 Lines) Fax: 2522225 E-mail: enquires@vadamalayan.org

Request No : 6198

Name : Mr Thameemudeen S,

Reg No : 17705

Ref . By : Srinivasan M

Reporting Date : 16-10-2012

Age / Sex : 39 Years / M

IP No : 2012A3114

Bed No/Ward : A23/GROUND FLOOR

ECHO

M – (Mode Measurement - cm)

LVID (d)	: 6.3	LID (s)	: 4.8
IVS (d)	: 1.0	IVS (s)	: 1.1
LVPW (d)	: 1.1	LVPW (s)	: 1.3
LA	: 3.3	AO	: 3.1
EF	: 47%	FS	: 24%

Mitral flow : E – 0.8 M/Sec, A – 0.4 M/Sec

Findings

- ☒ Left ventricle is mildly dilated
- ☒ Left ventricular function reduced (mild)
- ☒ All valve are normal
- ☒ IAS / IVS intact
- ☒ Anterior part of IVS anterior wall hypokinetic
- ☒ Grade I mitral regurgitation
- ☒ Tricuspid regurgitation – mild (TR jet : 2.5 M/Sec , 26mmHg)
- ☒ No pericardial effusion

Impression :

- ☒ Wall motion abnormality involving LAD territory
- ☒ Mild left ventricular dysfunction
- ☒ Grade I mitral regurgitation

VAN67 - 16-10-2012 / 20:23

Dr. M. Srinivasan, M.D., D.M.,
(Cardiologist)

